

# Randomized Placebo-Controlled, Double-Blind, Half-Head Study to Assess the Efficacy of Platelet-Rich Plasma on the Treatment of Androgenetic Alopecia

RUBINA ALVES, MD AND RAMON GRIMALT, MD, PhD

**BACKGROUND** Platelet-rich plasma (PRP) was identified as having a beneficial effect in alopecia and has been postulated as a new therapy for androgenetic alopecia (AGA).

**OBJECTIVE** To assess the efficacy of PRP for the treatment of AGA.

**MATERIALS AND METHODS** This was a randomized, placebo-controlled, double-blind study in 25 patients with AGA. Platelet-rich plasma was injected in half-head and the other half-head with placebo. Each patient received a total of 3 treatments of PRP, 1 month apart.

**RESULTS** Six months after the first treatment with PRP, significant differences were seen in mean anagen hairs ( $67.6 \pm 13.1$ ), telogen hairs ( $32.4 \pm 13.1$ ), hair density ( $179.9 \pm 62.7$ ), and terminal hair density ( $165.8 \pm 56.8$ ) when compared with baseline ( $p < .05$ ). Platelet-rich plasma was also found to increase hair density when comparing with the control side ( $p < .05$ ). For the first time, the authors found a correlation between anagen hairs and patients  $>40$  years and beginning of AGA  $\geq 25$  years old ( $p < .05$ ) and hair density and male sex, age  $\leq 40$  years, positive family history of AGA and  $>10$  years of duration of the disease ( $p < 0.05$ ).

**CONCLUSION** Application of PRP showed a positive effect on AGA and could be regarded as an adjuvant therapy for AGA.

*The authors have indicated no significant interest with commercial supporters.*

Androgenetic alopecia (AGA) is a nonscarring progressive miniaturization of the hair follicle with a typically characteristic pattern distribution in genetically predisposed men and women.<sup>1,2</sup> Until now, topical minoxidil and oral finasteride are the only approved drugs that Food and Drug Administration has for the treatment of AGA. Currently available treatments are at times perceived as having limited effectiveness, and finding new therapies for this pathology is therefore of utmost importance.<sup>3-6</sup>

Platelet-rich plasma (PRP) is an autologous preparation of platelets in concentrated plasma that contains a platelet concentration above basal concentration (150,000–350,000/L).<sup>7,8</sup> When platelet-alpha granules become activated, they

release numerous growth factors (GFs), such as platelet-derived growth factor, transforming growth factor-beta (TGF- $\beta$ ), vascular endothelial growth factor, epidermal growth factor, and insulin-like growth factor.<sup>7-13</sup> These GFs seem to stimulate cell proliferation and differentiation.<sup>10,14-16</sup>

Platelet-rich plasma was identified as having a beneficial effect on bone grafting with applications in oral and maxillofacial surgery, and orthopedic and cardiac surgery.<sup>9,10,17</sup> More recently, interest has been increasing in the application of PRP in dermatology, for example, in tissue regeneration, wound healing, fat grafting, and skin rejuvenating effects.<sup>7,18-22</sup> Recently, PRP has been postulated as a new therapy for AGA.

*Department of Dermatology, Universitat Internacional de Catalunya, Barcelona, Spain*

© 2016 by the American Society for Dermatologic Surgery, Inc. Published by Wolters Kluwer Health, Inc. All rights reserved.  
ISSN: 1076-0512 • *Dermatol Surg* 2016;42:491–497 • DOI: 10.1097/DSS.0000000000000665

In 2006, Uebel and colleagues<sup>14</sup> reported a new application of PRP for male pattern baldness surgery. This study showed that treatment of follicular units with PRP before transplantation resulted in improved hair growth and density. Since then, several studies<sup>3,4,7,10,14,23-26</sup> have been conducted worldwide to investigate the role of PRP for the treatment of hair loss, with a limited number of articles on PRP and AGA.

Despite these previous studies, the precise mechanism by which PRP promotes hair growth has not been properly studied.<sup>7</sup> The level of evidence of various studies in AGA is from low to medium,<sup>27</sup> and defined double-blind trials or split-face trials will definitely increase the confidence of clinicians with this procedure.<sup>28</sup>

Regarding the limited available literature, the authors performed a prospective randomized, double-blind placebo-controlled, half-head study on 25 patients with AGA, including 13 women. The main objective of this study was to evaluate the efficacy of treatment with PRP on AGA, between 3 months, 6 months, and baseline and to determine whether PRP could be considered a new effective treatment option for AGA.

## Materials and Methods

### Study Design

This study was a randomized, double-blind, placebo-controlled, half-head, parallel-group study on patients with AGA. After having received approval from the Ethical Committee of CEIC-UIC, the clinical protocol for the treatment of AGA was started in a private clinic linked to the Universitat Internacional Catalunya. All patients provided written informed consent before participating in the study, which was performed according to the Declaration of Helsinki.

### Participants

Participants were admitted in the study between January 2014 and November 2014. Men aged 18 to 65 years with Hamilton–Norwood Patterns II to V and women aged 18 to 65 years with Stage I to III according to Ludwig classification, who were otherwise healthy, were eligible for inclusion in this study.

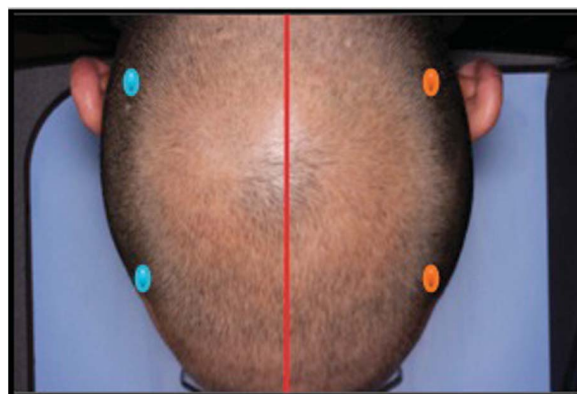
The exclusion criteria were as follows: use of any topical medication (such as minoxidil or any other solution for hair growth), oral medication (finasteride, dutasteride, or antiandrogens), laser therapy, or chemotherapy, within the preceding 12 months; bleeding disorders, platelet dysfunction syndrome, platelet counts <150,000 platelets per microliter ( $\mu\text{L}$ ); anticoagulant therapy or nonsteroidal anti-inflammatory drugs in the last 2 weeks; smokers (>20 cigarettes/day); and pregnancy or lactation. Patients were also excluded from the study if they had any chronic active scalp condition other than AGA or a history of hair transplants.

### Interventions

A complete blood cell count was performed in all patients at baseline. Only patients whose blood test had all parameters within the respective reference ranges were included in the study.

Eligible subjects were randomized in a ratio of 1:1 to receive a half-head treatment with PRP and the other half-head with placebo (saline solution). The patients were divided into 2 groups (A and B): Group A received treatment with PRP on the right half head and the placebo on the left half head, whereas Group B received treatment with PRP on the left half head and the placebo on the right half head (Fig. 1).

Briefly, to prepare PRP, 18 mL of peripheral blood was transferred to a tube with 2 mL of 3.8% sodium citrate.



**Figure 1.** Two identical circular areas of  $1 \times 1$  cm (1 frontal and 1 occipital) in both the treatment and control half heads were defined for TrichoScan analysis. The patient received treatment with PRP on the right half head and the placebo on the left half head (Group A).

The 20 mL citrated blood was centrifuged at 460g for 8 minutes (Omnigrafter-Proteal, Barcelona, Spain). The centrifugation process separated blood components owing to their different specific densities: an erythrocyte layer at the bottom of the tube, a PRP layer in the middle, and a platelet-poor plasma (PPP) layer at the top of the tube. Approximately 3/4 of the supernatant is discarded (PPP), and the resulting suspension is used as PRP (3 mL). The PRP obtained is a pure PRP (leukocyte poor), and the platelet count was on average approximately 3 times higher than in whole blood. The PRP fraction was separated and activated with 0.15 mL of 10% calcium chloride immediately before application. The PRP was injected on 4 selected areas of the scalp (marked with a dot tattoo) at the amount of 0.15 mL/cm<sup>2</sup>, using a 30-G needle. Local anesthesia was not used. No adverse events were recorded in this study, apart from local injection pain.

As a control, 3 mL of saline was injected into the opposing side of the experimental side. Because the characteristics and color of PRP are different from the placebo, the injecting physician is not blinded to the treatment modalities. The other physician, who is not aware of the side of the treatment, was responsible for the analyses of the data obtained and the evaluation of the treatment efficacy. The subjects remained blinded to the treatment (PRP or placebo) until the end of the study.

At the end of the study, all patients received 3 treatments of PRP on the previously nontreated half head (placebo area).

### **Assessment Criteria**

All patients were evaluated in 4 visits: V1, baseline and beginning of the study; V2, second treatment; V3, third treatment; and V4, follow-up. In the first 3 visits, a total of 3 treatments were given with an interval of 1 month from each other. The follow-up visit was the last visit, at 6 months to assess the efficacy of treatment compared with baseline. At baseline, 2 circular areas (1 frontal and 1 occipital) in both treatment and control half heads (4 circular areas) were defined and marked centrally with a red permanent tattoo. A dot tattoo guarantees the analysis of the same area to ensure the reproducibility of the study. The target areas were set symmetrically and according to the hair density. The results were compared

on similar locations: the right frontal area was compared with the left frontal area and the right posterior area was compared with the left posterior area.

The evaluation criteria were assessed in all patients by global photography and phototrichogram. The evaluator responsible for both global photographs and phototrichogram analyses was blinded with regard to the treatment and placebo areas and was not involved in the administration of treatment.

Global photographs of 3 areas of the scalp (vertex, frontal, and occipital) were performed using a medical photography system and software (Canon Canfield Orthostatic Device; OMNIA Digital Imaging System, Fairfield, NJ) to ensure that all patients were photographed consistently.

Phototrichograms were performed in all patients with the help of epiluminescence microscopy with digital image analysis (FotoFinder; TrichoScan Professional Version). Clippings of the 4 target areas were performed 48 hours before the phototrichograms were obtained. Using the TrichoScan software, all protocol-conformed pictures were analyzed to determine the treatment efficacy by measuring hair count (number of hairs/0.65 cm<sup>2</sup>), hair density, terminal hair density, anagen (%), telogen (%), and the anagen/telogen ratio.

### **Statistical Analyses**

Statistical analyses were performed using the mixed procedure SAS 9.2 (SAS Institute Inc., Cary, NC). Values of  $p < .05$  were regarded to be statistically significant. Data are presented as the mean  $\pm$  SDs.

### **Results**

Twelve men and 13 women with AGA were admitted in this study, of a total of 25 patients. Twenty-two patients (11 male and 11 women) completed the entire study; 3 patients were lost to follow-up. The mean age of enrolled subjects ( $n = 22$ ) was 39 years (age range: 21–62 years). The blood cell count performed in all patients at baseline had a mean platelet counting of  $1.523.82 \pm 35,000$  platelets/ $\mu$ L.

The hair growth parameters were measured after 3 months and 6 months and compared with the baseline (before treatment) and between treatment and control areas (placebo). At baseline, there were no significant differences in hair count, hair density, terminal density, and anagen or telogen hairs between the treatment and control areas of the scalp. Mean hair growth parameters for the treatment and control areas are shown in Table 1.

The results of this study revealed that the administration of PRP led to a statistically significant increase in the mean anagen hairs, telogen hairs, hair density, and terminal hair density after 3 months and after 6 months when compared with baseline (Fig.2)

Regarding the mean total hair density, the increase on the treated side was also found to be significant compared

with that on the control side. The mean total hair density for the treatment area after 3 months showed a mean increase of  $14.8 \pm 32.1$  hairs/cm<sup>2</sup> compared with baseline, whereas the control area showed a mean decrease of  $0.7 \pm 32.7$  hairs/cm<sup>2</sup> (control vs treatment,  $p < .05$ ). After 6 months, the treatment area with PRP had a mean increase of  $12.8 \pm 32.6$  hairs/cm<sup>2</sup> and the control area a decrease of  $2.1 \pm 31.3$  hairs/cm<sup>2</sup> (control vs treatment,  $p < .05$ ).

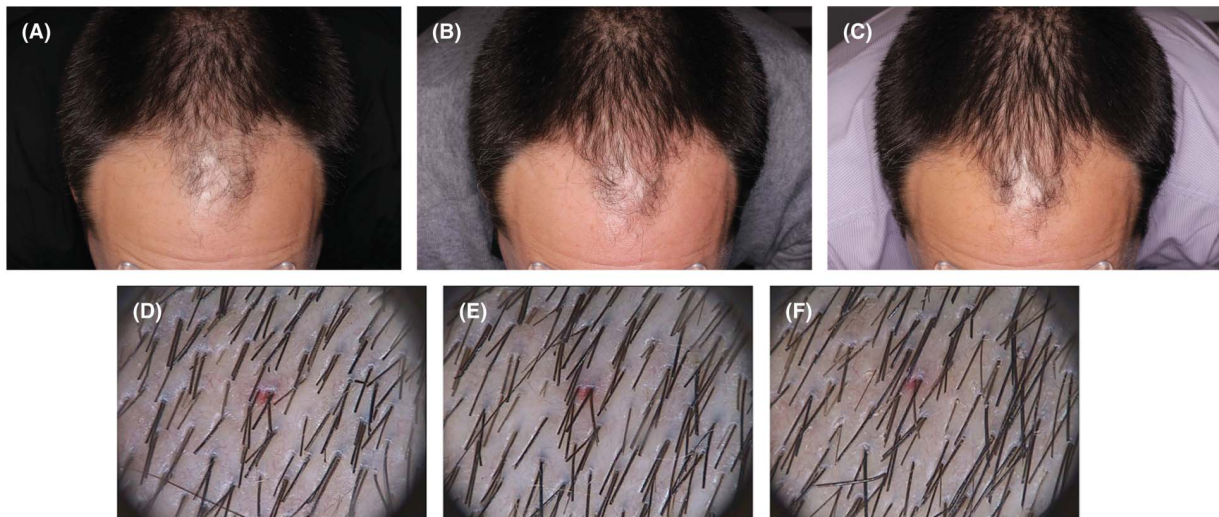
With respect to the number of total hair count, although there were no significant differences between the PRP-treated area and the placebo area, PRP exhibited a slight increase in number of hairs compared with the control group.

No differences in vellus hair density between the PRP and placebo areas were observed. In this study, an

**TABLE 1. Relevant Hair Growth Parameters for the Half-Head Areas Treated With PRP and Placebo at Baseline, 3 Months, and 6 Months**

	Placebo		PRP Treatment		Placebo vs PRP
	Mean ± SD	p	Mean ± SD	p	p
<b>Anagen hair (%)</b>					
Baseline	62.1 ± 17.4	>.05	62.1 ± 16.1	>.05	>.05
3 months	63.5 ± 18.9	>.05	67.9 ± 13.8	<b>&lt;.05</b>	>.05
6 months	66.3 ± 15.9	<b>&lt;.05</b>	67.6 ± 13.1	<b>&lt;.05</b>	>.05
<b>Telogen hair (%)</b>					
Baseline	37.9 ± 17.4	>.05	37.9 ± 16.1	>.05	>.05
3 months	34.5 ± 16.5	>.05	35.8 ± 14.4	<b>&lt;.05</b>	>.05
6 months	33.7 ± 15.9	<b>&lt;.05</b>	32.4 ± 13.1	<b>&lt;.05</b>	>.05
<b>Anagen/telogen ratio (%)</b>					
Baseline	137.5 ± 209.5	>.05	128.4 ± 174.8	>.05	>.05
3 months	159.1 ± 210.1	>.05	185.7 ± 199.9	<b>&lt;.05</b>	>.05
6 months	148.2 ± 173.1	>.05	156.0 ± 164.3	<b>&lt;.05</b>	>.05
<b>Hair density (1/cm<sup>2</sup>)</b>					
Baseline	167.8 ± 51.2	>.05	167.1 ± 55.6	>.05	>.05
3 months	167.1 ± 51.3	>.05	181.9 ± 63.6	<b>&lt;.05</b>	<b>&lt;.05</b>
6 months	165.7 ± 55.2	>.05	179.9 ± 62.7	<b>&lt;.05</b>	<b>&lt;.05</b>
<b>Terminal hair density (1/cm<sup>2</sup>)</b>					
Baseline	160 ± 48.9	>.05	159.9 ± 55.1	>.05	>.05
3 months	161.9 ± 52.2	>.05	168.2 ± 60.7	>.05	>.05
6 months	161.9 ± 52.2	>.05	165.8 ± 56.8	<b>&lt;.05</b>	>.05
<b>Hair count (hairs/0.65 cm<sup>2</sup>)</b>					
Baseline	111 ± 33.9	>.05	110.8 ± 37.6	>.05	>.05
3 months	112 ± 35.7	>.05	115 ± 41.8	>.05	>.05
6 months	112.7 ± 34.9	>.05	113.2 ± 39.4	>.05	>.05

Data assessed by TrichoScan Analysis.  
 Bold values indicate statistical significance  $p < 0.05$ .



**Figure 2.** A 34-year-old man with AGA treated with PRP on the right half head and placebo on the left half head. Global photographs of the scalp performed at baseline (A), 3 months (B), and 6 months (C). Phototrichograms (20-fold magnification) performed at baseline (D), 3 months (E), and 6 months (F).

analysis of each hair growth parameter and subject demographic characteristics was performed (Table 2).

In support of the data obtained, treatment with PRP showed a statistically significant correlation of the mean total hair density between men, patients aged  $\leq 40$  years, beginning of hair loss  $\geq 25$  years, positive family history, and  $>10$  years of evolution of AGA, when compared with the placebo. This study also found a correlation in the areas treated with PRP between anagen hairs (%), and patients aged more than 40 years and beginning of AGA  $\geq 25$  years, at 6 months. The other parameters analyzed did not show statistical differences.

## Discussion

In this double-blind, half-head, and placebo-controlled study, the authors have demonstrated that the administration of PRP attended a statistically significant improvement of mean anagen hairs, telogen hairs, hair density, and terminal hair density at 3 months and 6 months, when compared with baseline. However, when comparing to the control side, the hair on the PRP-treated side showed a statistically significant increase in mean total hair density only. The underlying mechanism of how administration of PRP induces a positive effect on AGA is not clear.

Li and colleagues<sup>7</sup> studied the effect of PRP on hair growth using *in vitro* and *in vivo* (mice) models. They

proposed that the injection of mice with activated PRP induced a faster telogen-to-anagen transition than was seen in the control mice. Anagen-associated angiogenesis has been suggested to be one of the most important factors in active hair growth.<sup>26</sup> This study provides further support that pure PRP may prolong the anagen phase of the hair cycle, as the authors found a superior anagen/telogen ratio (%) in the areas treated with PRP than the areas treated with the placebo, when compared with baseline.

In a study performed by Lopez and colleagues,<sup>29</sup> patients treated with PRP showed a significant correlation between male sex and the hair density. As in the latter article, beside this correlation, in this study, the authors were also able to demonstrate for the first time a statistical significant association between hair density and patients below 40 years with positive family history of AGA and more than 10 years of duration of the disease. In addition, to the best of the authors' knowledge, this study is also the first in which there is a correlation between anagen hairs and patients older than 40 years and beginning of AGA with age superior to 25 years.

This study has the limitation of having a follow-up of 6 months. Furthermore, a follow-up period of 6 months is short to draw final conclusions about the benefits of treatment with PRP over time. However, in this study, a single patient played the role of both treated and

**TABLE 2. Analysis of Hair Growth Parameters (Hair Density and Anagen Hairs) and Subject Demographic Characteristics**

Mean Total	Placebo	PRP	Placebo vs PRP
	Median ± SD	Median ± SD	p
<b>Hair density (1/cm<sup>2</sup>)</b>			
Women	2.7 ± 30.7	11.1 ± 29.6	>.05
Men	0.8 ± 31.6	14.3 ± 36.2	<b>&lt;.05</b>
Age ≤40 years	4.1 ± 31.5	9.4 ± 35.5	<b>&lt;.05</b>
Age >40 years	7.5 ± 30.0	17.6 ± 29.0	>.05
Beginning of AGA <25 years	5.1 ± 29.3	1.9 ± 27.2	>.05
Beginning of AGA ≥25 years	10.6 ± 32.7	30.4 ± 34.3	<b>&lt;.05</b>
Family history, +	1.9 ± 31.9	14.7 ± 34.1	<b>&lt;.05</b>
Family history, -	2.9 ± 29.0	5.2 ± 29.4	>.05
Disease duration ≤10 years	5.8 ± 38.6	16.4 ± 33.2	>.05
Disease duration >10 years	3.2 ± 23.0	9.7 ± 32.8	<b>&lt;.05</b>
<b>Anagen hair (%)</b>			
Women	1.8 ± 15.5	3.3 ± 11.3	>.05
Men	4.1 ± 12.9	5.5 ± 11.1	>.05
Age ≤40 years	5.1 ± 14.8	4.4 ± 11.0	>.05
Age >40 years	0.8 ± 13.6	4.5 ± 11.3	<b>&lt;.05</b>
Beginning of AGA <25 years	6.0 ± 14.4	4.9 ± 9.9	>.05
Beginning of AGA ≥25 years	1.9 ± 13.8	3.9 ± 13.0	<b>&lt;.05</b>
Family history, +	4.3 ± 12.7	5.2 ± 11.5	>.05
Family history, -	2.9 ± 29.0	5.2 ± 29.4	>.05
Disease duration ≤10 years	2.6 ± 14.4	4.5 ± 11.8	>.05
Disease duration >10 years	3.4 ± 14.2	4.4 ± 10.9	>.05

Bold values indicate statistical significance *p* < 0.05.

controlled subject. This has advantages because it could correct the possible biases such as gender and grade of hair loss that could affect the results.

Data analyzed from different studies<sup>7,10,14,25,29-33</sup> demonstrated an increase in number of hairs and/or hair density in patients treated with PRP. Most studies are open label and not blinded, making it difficult to reproduce the results and perform comparisons between them.<sup>22</sup> Also, there is a large heterogeneity in PRP preparation with many devices available, which makes more difficult the interpretation of the results. Some studies also included modifications or other types of PRP, such as dalteparin/protamine<sup>10</sup> and leukocyte PRP.<sup>4</sup>

Although the literature about PRPs developed with all these contradictions, the need for standardized terminology is of maximum importance.<sup>34,35</sup> Thus, some classifications have been proposed to achieve a consensus terminology in the field of platelet concentrates.<sup>36-39</sup>

Characterizing the type of PRP used (as a pure PRP, in this study) will lead to a better understanding of PRP, and data available will be easier to sort and interpret. Also, this terminology would serve as a basis for further research on the topic.

**Conclusions**

This clinical research provides support that the application of PRP may have a therapeutic effect on AGA and can be used as a safe complementary treatment option. However, more controlled and well-designed clinical trials should be conducted to confirm the clinical improvement of AGA with administration of PRP.

Furthermore, other clinical trial that includes a larger sample of patients with AGA, simultaneously treated with PRP and other topical and/or oral medications for hair growth, would also help define the efficacy of PRP as an adjuvant treatment of AGA.

## References

- Kaliyadan F, Nambiar A, Vijayaraghavan S. Androgenetic alopecia: an update. *Indian J Dermatol Venereol Leprol* 2013;79:613–25.
- De Rivero Vaccari JP, Sawaya ME, Brand F III, Nusbaum BP, et al. Caspase-1 level is higher in the scalp in androgenetic alopecia. *Dermatol Surg* 2012;38(7 Pt 1):1033–9.
- Trink A, Sorbellini E, Bezzola P, Rodella L, et al. A randomized, double-blind, placebo- and active-controlled, half-head study to evaluate the effects of platelet-rich plasma on alopecia areata. *Br J Dermatol* 2013;169:690–4.
- Schiavone G, Raskovic D, Greco J, Abeni D. Platelet-rich plasma for androgenetic alopecia: a pilot study. *Dermatol Surg* 2014;40:1010–9.
- Kim H, Choi JW, Kim JY, Shin JW, et al. Low-level light therapy for androgenetic alopecia: a 24-week, randomized, double-blind, sham device-controlled multicenter trial. *Dermatol Surg* 2013;39:1177–83.
- Falto-Aizpurua L, Choudhary S, Tosti A. Emerging treatments in alopecia. *Expert Opin Emerg Drugs* 2014;19:545–56.
- Li ZJ, Choi HI, Choi DK, Sohn KC, et al. Autologous platelet-rich plasma: a potential therapeutic tool for promoting hair growth. *Dermatol Surg* 2012;38(7 Pt 1):1040–6.
- Conde Montero E, Fernández Santos ME, Suárez Fernández R. Platelet-rich plasma: applications in dermatology. *Actas Dermosifiliogr* 2015;106:104–11.
- Roukis TS, Zgonis T, Tiernan B. Autologous platelet-rich plasma for wound and osseous healing: a review of the literature and commercially available products. *Adv Ther* 2006;23:218–37.
- Takikawa M, Nakamura S, Nakamura S, Ishirara M, et al. Enhanced effect of platelet-rich plasma containing a new carrier on hair growth. *Dermatol Surg* 2011;37:1721–9.
- Singh MK. Commentary on 'Platelet-rich plasma for androgenetic alopecia: a pilot study'. *Dermatol Surg* 2014;40:1020–1.
- Marx RE. Platelet-rich plasma: evidence to support its use. *J Oral Maxillofac Surg* 2004;62:489–96.
- Eppley BL, Pietzak WS, Blanton M. Platelet-rich plasma: a review of Biology and applications in plastic surgery. *Plast Reconstr Surg* 2006;118:147e–59e.
- Uebel CO, da Silva JB, Cantarelli D, Martins P. The role of platelet plasma growth factors in male pattern baldness surgery. *Plast Reconstr Surg* 2006;118:1458–66.
- Paus R. Do we need hair follicle stem cells, hair follicle neogenesis to cure common hair loss disorders? *Hair Transp Forum Int* 2008;18:89–90.
- Garza LA, Yang CC, Zhao T, Blatt HB, et al. Bald scalp in men with androgenetic alopecia retains hair follicle stem cells but lacks CD200-rich and CD34-positive hair follicle progenitor cells. *J Clin Invest* 2011;121:613–22.
- Rogers N. Commentary on Autologous platelet-rich plasma: a potential therapeutic tool for promoting hair growth. *Dermatol Surg* 2012;38(7 Pt 1):1047–8.
- Sommeling CE, Heyneman A, Hoeksema H, Verbelen J, et al. The use of platelet-rich plasma in plastic surgery: a systematic review. *J Plast Reconstr Aesthet Surg* 2013;66:301–11.
- Salazar-Álvarez AE, Riera-del-Moral LF, García-Arranz M, Álvarez-García J, et al. Use of platelet-rich plasma in the healing of chronic ulcers of the lower extremity. *Actas Dermosifiliogr* 2014;105:597–604.
- Picard F, Hersant B, Bosc R, Meningaud JP. Should we use platelet-rich plasma as an adjunct therapy to treat “acute wounds,” “burns,” and “laser therapies”: a review and a proposal of a quality criteria checklist for further studies. *Wound Repair Regen* 2015;23:163–70.
- Cobos R, Aizpuru F, Parraza N, Anitua E, et al. Effectiveness and efficiency of platelet rich plasma in the treatment of diabetic ulcers. *Curr Pharm Biotechnol* 2015;16:630–4.
- Sclafani AP, Azzi J. Platelet preparations for use in facial rejuvenation and wound healing: a critical review of current literature. *Aesthet Plast Surg* 2015;39:495–505.
- Singh S. Role of platelet-rich plasma in chronic alopecia areata: our centre experience. *Indian J Plast Surg* 2015;48:57–9.
- Gkini MA, Kouskoukis AE, Tripsianis G, Rigopoulos D, et al. Study of platelet-rich plasma injections in the treatment of androgenetic alopecia through an one-year period. *J Cutan Aesthet Surg* 2014;7:213–9.
- Cervelli V, Garcovich S, Bielli A, Cervelli G, et al. The effect of autologous activated platelet rich plasma (AA-PRP) injection on pattern hair loss: clinical and histomorphometric evaluation. *Biomed Res Int* 2014;2014:760709.
- Kang JS, Zheng Z, Choi MJ, Lee SH, et al. The effect of CD34+ cell-containing autologous platelet-rich plasma injection on pattern hair loss: a preliminary study. *J Eur Acad Dermatol Venereol* 2014;28:72–9.
- Arshdeep, Kumaran MS. Platelet-rich plasma in dermatology: boon or a bane? *Indian J Dermatol Venereol Leprol* 2014;80:5–14.
- Godse K. Platelet rich plasma in Androgenic alopecia: where do we Stand? *J Cutan Aesthet Surg* 2014;7:110–1.
- Lopez V, Vaya A, Bautista D, Ricart JM. Autologous platelet-rich plasma as a potential therapeutic tool in androgenetic alopecia. *J Am Acad Dermatol* 2013;68:SAB103.
- Greco J, Brandt R. The effects of autologous platelet rich plasma and various growth factors on non-transplanted miniaturized hair. *Hair Transp Forum Int* 2009;19:49–50.
- Park KY, Kim HK, Kim BJ, Kim MN. Platelet-rich plasma for treating male pattern baldness. *Dermatol Surg* 2012;38:2042–4.
- Rinaldi F, Sorbellini E, Coscera T. The role of platelet rich plasma to control anagen phase: evaluation in vitro and in vivo in hair transplant and hair treatment. *Int J Trichol* 2011;3:S14–5.
- Miao Y, Sun Y, Sun X, Du B, et al. Promotional effect of platelet-rich plasma on hair follicle reconstitution in vivo. *Dermatol Surg* 2013;39:1868–76.
- Anitua E, Sánchez M, Orive G. The importance of understanding what is platelet-rich growth factor (PRGF) and what is not. *J Shoulder Elbow Surg* 2011;20:e23–4.
- De Pascale MR, Sommese L, Casamassimi A, Napoli C. Platelet derivatives in regenerative medicine: an update. *Transfus Med Re* 2015;29:52–61.
- Dohan Ehrenfest DM, Sammartino G, Shibli JA, Wang HL, et al. Guidelines for the publication of articles related to platelet concentrates (Platelet-Rich Plasma—PRP, or Platelet-Rich Fibrin—PRF): the international classification of the POSEIDO. *POSEIDO* 2013;1:17–27.
- Dohan Ehrenfest DM, Rasmusson L, Albrektsson T. Classification of platelet concentrates: from pure platelet-rich plasma (P-PRP) to leucocyte- and platelet-rich fibrin (L-PRF). *Trends Biotechnol* 2009;2:158–67.
- Dohan Ehrenfest DM, Bielecki T, Mishra A, Borzini P, et al. In search of a consensus terminology in the field of platelet concentrates for surgical use: platelet-rich plasma (PRP), platelet-rich fibrin (PRF), fibrin gel polymerization and leukocytes. *Curr Pharm Biotechnol* 2012;13:1131–7.
- Mishra A, Harmon K, Woodall J, Vieira A. Sports medicine applications of platelet rich plasma. *Curr Pharm Biotechnol* 2012;13:1185–95.

Address correspondence and reprint requests to: Rubina Alves, MD, Universitat Internacional de Catalunya, Estrada Monumental, 364 3F, Funchal, Portugal 9000-100, or e-mail: rubinaalves@gmail.com